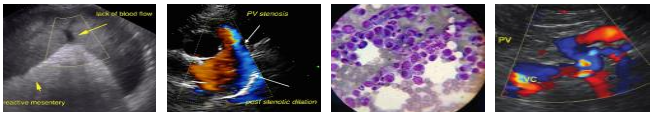

SonoPath.com
1-800-838-4268 info@sonopath.com

DATE

1/4/22

PERFORMED BY:

Amy Mayhew, LVT

INTERPRETED BY

Keith Blass, DVM, MS, DACVIM (Cardiology)

PATIENT

Reginald Congdon

SPECIES

Feline

BREED

DSH

SEX

MN

AGE

12 y

WEIGHT

11.8 lb

HOSPITAL NAME

SVS Imaging MI

REFERRING VET

Family Pet Practice

PRESENTING CLINICAL SIGNS

History: Hemangiosarcoma removed from right lateral abdomen in September. Doing well. No murmur.

ECHOCARDIOGRAPHIC FINDINGS

2D, M-mode, and Doppler study.

Left atrial size is normal. The mitral valve is normal. Left ventricular wall thickness is normal. Left ventricular internal dimensions are normal. Left ventricular systolic function is hyperdynamic. The aorta and aortic valve appear normal. Right atrial and right ventricular dimensions are normal. The tricuspid valve is normal. The pulmonary artery and pulmonic valve are normal. No shunting lesions are visualized. No pericardial effusion or cardiac masses are seen.

LA/Ao – 1.13
IVSd – 5.2 mm
LVPWd – 5.1 mm
LVIDd – 12.4 mm
LVIDs – 5.0 mm
FS – 59.7%
RVOT – 0.72 m/s

ASSESSMENT/RECOMMENDATIONS

Normal echocardiogram

This examination demonstrates no evidence of structural heart disease, nor does it demonstrate any evidence of cardiac neoplasia.

No therapy is recommended based on this exam.

A recheck echocardiogram is recommended if new physical exam and/or clinical abnormalities suggestive of cardiac dysfunction develop.

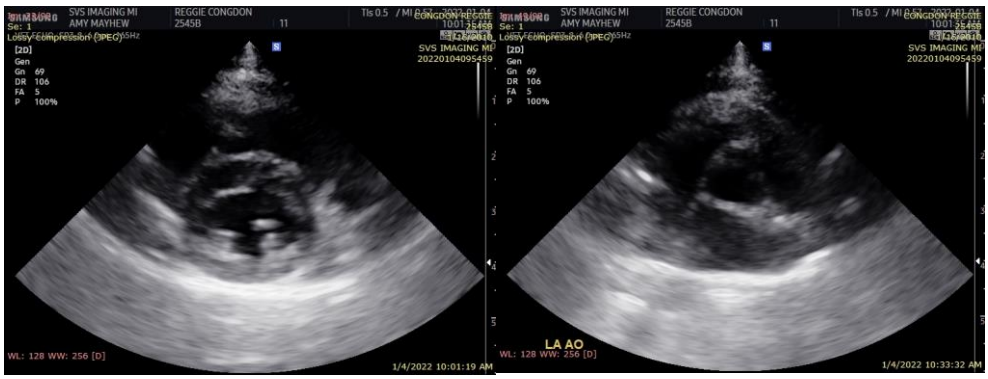

The information and recommendations provided are based on the images presented by the referring veterinarian. No evaluation can be communicated regarding pathology that was not visible in the image/video clips provided.

Thank you for this referral. If the clinical or image interpretation does not parallel your findings or if I can be of any further assistance please contact me.

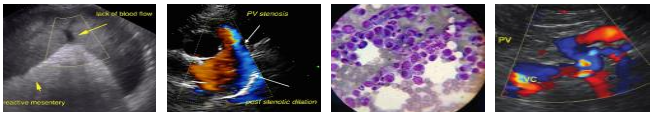

SonoPath.com
1-800-838-4268 info@sonopath.com

Keith Blass, DVM, MS, DACVIM (Cardiology)
KeithBlass@gmail.com
631-804-5754

DATE

1/4/22

PERFORMED BY:

Amy Mayhew, LVT

INTERPRETED BY

Keith Blass, DVM, MS, DACVIM (Cardiology)

PATIENT

Reginald Congdon

SPECIES

Feline

BREED

DSH

SEX

MN

AGE

12 y

WEIGHT

11.8 lb

HOSPITAL NAME

SVS Imaging MI

REFERRING VET

Family Pet Practice